

Retrograde mechanochemical ablation of the small saphenous vein for the treatment of a venous ulcer

Hayley M Moore, Tristan RA Lane, Ian J Franklin and Alun H Davies

Vascular published online 17 December 2013

DOI: 10.1177/1708538113516320

The online version of this article can be found at:

<http://vas.sagepub.com/content/early/2013/12/17/1708538113516320>

Published by:



<http://www.sagepublications.com>

Additional services and information for *Vascular* can be found at:

Email Alerts: <http://vas.sagepub.com/cgi/alerts>

Subscriptions: <http://vas.sagepub.com/subscriptions>

Reprints: <http://www.sagepub.com/journalsReprints.nav>

Permissions: <http://www.sagepub.com/journalsPermissions.nav>

>> [OnlineFirst Version of Record](#) - Dec 17, 2013

[What is This?](#)

Retrograde mechanochemical ablation of the small saphenous vein for the treatment of a venous ulcer

Hayley M Moore, Tristan RA Lane, Ian J Franklin and Alun H Davies

Abstract

We present the first case of retrograde ablation of the small saphenous vein to treat active venous ulceration. A 73-year-old gentleman with complicated varicose veins of the left leg and a non-healing venous ulcer despite previous successful endovenous treatment to his left great saphenous vein underwent mechanochemical ablation of his small saphenous vein with the ClariVein[®] system, under local anaesthetic, using a retrograde cannulation technique. Post-operatively the patient had improved symptomatically and the ulcer size had reduced. This report highlights that patients with small saphenous vein incompetence and active ulceration can be treated successfully with retrograde mechanochemical ablation.

Keywords

ClariVein, varicose veins, endovenous ablation, mechanochemical ablation, ulcer

Introduction

Venous ulceration is generally treated with compression therapy, but work by Gohel et al.¹ showed that surgical intervention was effective at preventing ulcer recurrence. More recent evidence from Kulkarni et al.² and Pang et al.³ demonstrated that ultrasound-guided foam sclerotherapy improved ulcer healing rates compared to historical data. Mechanochemical superficial vein ablation using the ClariVein[®] (Vascular Insights LLC of Madison, CT, USA) catheter does not require tumescent anaesthesia and has good treatment outcomes.⁴

Twenty two percent of patients with venous ulceration have small saphenous vein (SSV) incompetence.⁵ In the presence of active ulceration, open surgery and distal endovenous ablation techniques requiring cannulation and tumescent anaesthesia may risk the introduction of infection. The use of ultrasound-guided foam sclerotherapy has been described, however ablation rates are variable.^{2,6–8}

In this report, we present the first case of retrograde ablation of the SSV to treat active venous ulceration.

Case report

A 73-year-old gentleman presented to the clinic at Charing Cross Hospital with complicated varicose

veins of the left leg, with a non-healing 4-cm diameter venous ulcer present for more than 1 year. He had a Clinical Etiological Anatomical Pathological (CEAP) score of C6bS Ep Asd Pr, an Aberdeen Varicose Vein Questionnaire (AVVQ) score of 23.85,⁹ an EQ-5D 0.666, EQ-VAS 70¹⁰ and a VCSS of 16.¹¹ He had a history of type II diabetes mellitus and a past history of prostate cancer, which had been treated with radiotherapy. A venous duplex ultrasound revealed refluxing (>0.5 seconds reflux time) disease of both the great saphenous vein (GSV) and SSV as well as an incompetent deep venous system. The GSV was 7.2 millimetres in maximal diameter and the SSV maximal diameter was 12 millimetres in maximal diameter. He underwent endovenous treatment to his left GSV, following which his pain improved and the size of the ulcer reduced from 4 cm to 2 cm diameter. However, after 6 months of adequate compression with the three-layer bandaging technique, the ulcer had failed to fully heal and his symptoms worsened. A repeat venous duplex scan

Academic Section of Vascular Surgery, Imperial College London, London

Corresponding author:

Tristan RA Lane, 4 North, Academic Section of Vascular Surgery, Imperial College London, Charing Cross Hospital, Fulham Palace Road, W6 8RF, London, UK.

Email: tristan.lane@imperial.ac.uk

demonstrated occlusion of the GSV and persisting reflux in the SSV and the femoral and popliteal veins. The patient underwent mechanochemical ablation of his SSV under local anaesthetic in August 2012. The procedure was as follows:

The SSV was cannulated under ultrasound guidance at the SSV fascial curve in the popliteal fossa and the ClariVein® catheter was passed distally using standard Seldinger technique in a prone reverse Trendelenberg position. The patient angle was then flattened. Using standard mechanochemical ablation technique⁴ and 4ml 2% Fibrovein® (sodium tetradecyl sulphate), 20cm of the SSV was ablated. The puncture site was closed with a Steri-Strip dressing (3M, St. Paul, Minn) and a cannulation site plaster (Mepore; Mölnlycke Health Care, Gothenburg, Sweden) without sutures. A schematic of the technique is demonstrated by Figure 1, with a clinical photo of the equipment in Figure 2. Adequate compression with the three-layer bandaging technique was continued until ulcer healing.

At 3-month follow up, subjectively, he had experienced no post-operative pain or inflammation. The patient had improved symptomatically, increasing his daily activities due to a reduction in the pain from his ulcer. The ulcer size had reduced to 3 mm with evidence of granulating tissue at the base. His AVVQ had not

improved – 24.82 (5% deterioration) – however, the EQ-5D 0.735 (10% improvement) and EQ-VAS of 80 (14% improvement) were both markedly improved and his VCSS score was improved to 12 (25% improvement). Repeat venous duplex ultrasound at 3 months showed successful SSV occlusion and a competent deep venous system.

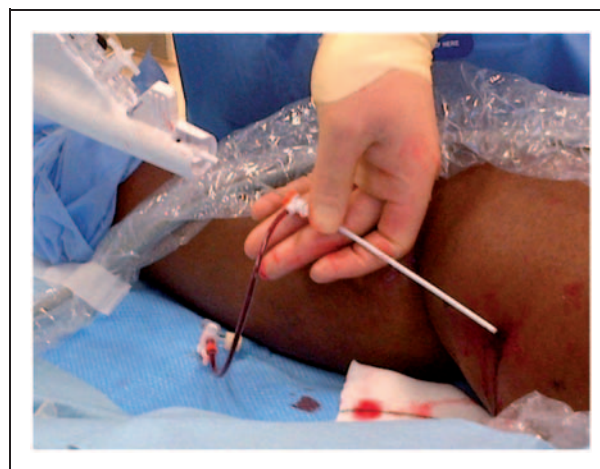

Figure 2. Clinical picture of ClariVein mechanochemical ablation device in use.

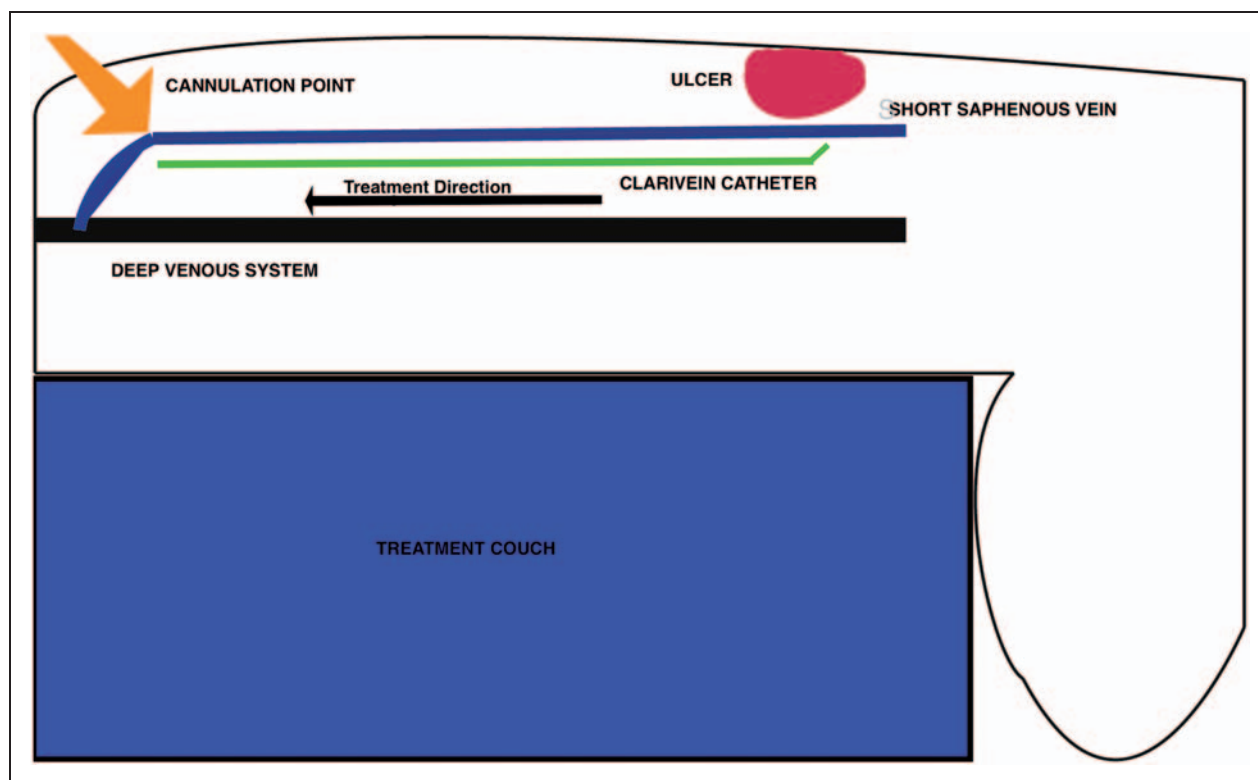


Figure 1. Schematic of retrograde ClariVein procedure.

Discussion

In this report, we demonstrate that retrograde venous ablation using a non-thermal modality is feasible with a catheter-based technique such as the ClariVein® device. A mechanochemical catheter device allows distal treatment without the risk of nerve damage due to thermal injury. This retrograde technique ensures that the cannulation site is distant from the site of ulceration, which may reduce the risk of infection, with the added benefit that no additional skin punctures are required for tumescent anaesthesia. However, the current rate of infection during ablation runs at 0.3% and so the improvement will be minor. Historic infection rates of 4–8% have been reported in the context of general anaesthetic with simultaneous adjunctive phlebectomies^{12–14} and the one notable report of sepsis after endovenous treatment was treatment of an ulcer with endovenous ablation and phlebectomies under general anaesthetic.¹⁵

The segment of vein underlying the area of ulceration can also be treated using this technique, meaning a longer segment of vein can be ablated. The technique could also be applied to treat both the distal GSV in the presence of ulcerations and in the future may allow precise access to problematic incompetent veins extending under active ulceration.

Further patients have also been treated with this approach with good closure rates and improvements in symptomatology and ulcer status. The normalisation of deep venous reflux on treatment of superficial reflux has been previously described after surgery.^{16,17}

Use of the ClariVein® device for retrograde treatment has a good margin of safety as the amount of liquid sclerosant used is small and the active treatment area is 2 cm distant to the cannulation site to prevent skin damage. Coupled with a vein in spasm and a catheter impeding flow, proximal passage of sclerosant into the deep venous system before deactivation by blood is highly unlikely.

Conclusion

This report highlights the expanding possibilities for treatment of venous ulceration. Patients with SSV incompetence and active ulceration can be treated successfully with retrograde mechanochemical ablation whilst maintaining sterility.

Conflict of interest

None declared

Funding

The research was supported by the National Institute for Health Research (NIHR) Biomedical Research Centre based at Imperial College Healthcare NHS Trust and

Imperial College London. The views expressed are those of the authors and not necessarily those of the NHS, NIHR or the Department of Health. The research was funded by the Royal Society of Medicine, Graham-Dixon Charitable Trust and the Royal College of Surgeons of England.

References

1. Gohel MS, Barwell JR, Taylor M, et al. Long term results of compression therapy alone versus compression plus surgery in chronic venous ulceration (ESCHAR): randomised controlled trial. *BMJ* 2007; 335: 83.
2. Kulkarni SR, Slim FJ, Emerson LG, et al. Effect of foam sclerotherapy on healing and long-term recurrence in chronic venous leg ulcers. *Phlebology* 2013; 28: 140–146.
3. Pang KH, Bate GR, Darvall KA, et al. Healing and recurrence rates following ultrasound-guided foam sclerotherapy of superficial venous reflux in patients with chronic venous ulceration. *Eur J Vasc Endovasc Surg* 2010; 40: 790–795.
4. Elias S and Raines JK. Mechanochemical tumescentless endovenous ablation: final results of the initial clinical trial. *Phlebology* 2012; 27: 67–72.
5. Obermayer A and Garzon K. Identifying the source of superficial reflux in venous leg ulcers using duplex ultrasound. *J Vasc Surg* 2010; 52: 1255–1261.
6. Ascitto G and Lindblad B. Catheter-directed foam sclerotherapy treatment of saphenous vein incompetence. *Vasa* 2012; 41: 120–124.
7. Darvall KA, Bate GR, Adam DJ, et al. Duplex ultrasound outcomes following ultrasound-guided foam sclerotherapy of symptomatic recurrent great saphenous varicose veins. *Eur J Vasc Endovasc Surg* 2011; 42: 107–114.
8. Lattimer CR, Azzam M, Kalodiki E, et al. Cost and effectiveness of laser with phlebectomies compared with foam sclerotherapy in superficial venous insufficiency. Early results of a randomised controlled trial. *Eur J Vasc Endovasc Surg* 2012; 43: 594–600.
9. Garratt AM, Macdonald LM, Ruta DA, et al. Towards measurement of outcome for patients with varicose veins. *Qual Health Care* 1993; 2: 5–10.
10. EuroQol—a new facility for the measurement of health-related quality of life. The EuroQol Group. *Health Policy* 1990; 16: 199–208.
11. Vasquez MA, Rabe E, McLafferty RB, et al. Revision of the venous clinical severity score: venous outcomes consensus statement: special communication of the American Venous Forum Ad Hoc Outcomes Working Group. *J Vasc Surg* 2010; 52: 1387–1396.
12. Shepherd AC, Gohel MS, Brown LC, et al. Randomized clinical trial of VNUS ClosureFAST radiofrequency ablation versus laser for varicose veins. *Br J Surg* 2010; 97: 810–818.
13. Anwar MA, Lane TR, Davies AH, et al. Complications of radiofrequency ablation of varicose veins. *Phlebology* 2012; 27: 34–39.
14. van den Bos R, Arends L, Kockaert M, et al. Endovenous therapies of lower extremity varicosities: a meta-analysis. *J Vasc Surg* 2009; 49: 230–239.

15. Dunst KM, Huemer GM, Wayand W, et al. Diffuse phlegmonous phlebitis after endovenous laser treatment of the greater saphenous vein. *J Vasc Surg* 2006; 43: 1056–1058.
16. MacKenzie RK, Allan PL, Ruckley CV, et al. The effect of long saphenous vein stripping on deep venous reflux. *Eur J Vasc Endovasc Surg* 2004; 28: 104–107.
17. Walsh JC, Bergan JJ, Beeman S, et al. Femoral venous reflux abolished by greater saphenous vein stripping. *Ann Vasc Surg* 1994; 8: 566–570.